

LAPAROSCOPIC CHOLECYSTECTOMY IN SITUS INVERSUS: ENVISION AND DEXTERITY OF A SURGEON MAKE IT SAFE

Rinki Das¹, Soham Patra², Ritankar Sengupta³

¹Associate Professor, Department of General Surgery, IPGME&R- SSKM Hospital, Kolkata, India.

²Senior Resident, Department of General Surgery, IPGME&R- SSKM Hospital, Kolkata, India.

³Associate Professor, Department of General Surgery, Burdwan Medical College, West Bengal, India.

Received : 25/03/2023
Received in revised form : 22/04/2023
Accepted : 05/05/2023

Keywords:

Laparoscopic cholecystectomy, situs inversus, left sided gall bladder.

Corresponding Author:

Dr. Ritankar Sengupta,

Email: dritankarsengupta@gmail.com

DOI: 10.47009/jamp.2023.5.5.129

Source of Support: Nil,
Conflict of Interest: None declared

Int J Acad Med Pharm
2023; 5 (5); 664-666



Abstract

Laparoscopic Cholecystectomy in left sided gall bladder is technically demanding. Most of the left sided gall bladders are associated with situs inversus. Here we present four cases of laparoscopic cholecystectomy in situs inversus patients with special emphasis on the technical modifications. All the patients enjoyed normal postoperative recovery.

INTRODUCTION

Although laparoscopic cholecystectomy is the standard procedure for treating benign gall bladder disorders, cholecystectomy for left sided gall bladder is a bit challenging for the majority right-handed surgeons. For cholecystectomy in situs inversus patients the procedure is not simply about following mirror images, but technical alterations during dissection and modified use of instruments are also crucial.^[1,2] In this paper we tried to give a brief account of our experience of doing cholecystectomy in situs inversus patients with technical details.

CASE SERIES

Preparation of mind to follow the mirror images of all the steps of the procedure is a prerequisite for the surgeon. Left-handed surgeons may have an edge over the right-handed surgeons while carrying out the dissection. Preoperative computed tomography or magnetic resonance imaging may be helpful for identification of any bilio-vascular anomaly beforehand and all our patients were evaluated with magnetic resonance cholangiography. A debriefing session with the team members makes the procedure fast and effortless.

The technical details: Technical modifications start from positioning the monitor and insufflator to the left of the patient. The surgeon may stand to the right of the patient or may adopt a French position. In our series three cases were performed with the surgeon

standing on patient's right side and French position was adopted for one patient where the patient was placed in Lloyd-davies with reverse trendelenburg and left up position and the surgeon stood in between legs [Table 1, * Lloyd davies position]. A 30 degree telescope was of particular help.

Four ports were introduced mirroring the traditional port placement with infra umbilical 10 mm camera port, epigastric 10 mm port entering the abdomen to the left of falciform ligament, and two 5 mm port along the left subcostal region at the mid clavicular and anterior axillary fold with adjustments for the position of gall bladder fundus.

Identification of structures at the Calot's triangle is crucial as any laparoscopic cholecystectomy procedure [Figure 1]. Most of the Calot's triangle dissection was carried out through the posterior peritoneal fold, with the right-hand instrument through the left mid-clavicular port, not mirroring the traditional technique where the dissecting instrument is used through the epigastric port. Any remaining dissection through the anterior peritoneal fold needs instrument crossover or use of left-hand dissection by the right-handed surgeon. At this point we rearranged the retraction on the gall bladder. Retraction of gall bladder was shifted from fundus to the infundibulum by the second assistant. This allows the principal surgeon to use his dominant hand for the dissection through the left midclavicular port while retracting the gall bladder fundus using a grasper through the epigastric port. The shaft of the grasper also retracted the hanging left lobe of the liver. This helps avoiding instrument crossover and eases the anterior peritoneal

fold dissection by a right-handed surgeon. However, this step needs good co-ordination between the operating surgeon and the second assistant. For one case the suction cannula was used to retract the left lobe of liver to open up the anterior peritoneal fold and pushing the gallbladder fundus gently using the tip of the cannula.

Once critical view of safety was achieved, clipping of cystic artery and cystic duct were done. The clip applicator was put through the epigastric port with surgeon using left hand, and this was relatively easy

for a right-handed surgeon. Scissors were used with right hand through left midclavicular port [Figure 2] Alternatively the 5 mm mid-clavicular port can be converted to another 10 mm port for anterior peritoneal fold dissection and clip application and this was adopted in two cases.

Dissection of gall bladder fossa was carried out from posterior fold to the anterior fold using a spatula and/or a hook as required. Gall bladder retrieval was done through the umbilical port in retrieval bag.

Table 1: Clinical presentation of four cases with gall stone diseases in situs inversus patients

Sl No	Age/Gender	Complaints	Type of situs	Operating time	Complication	Histopathology
1	36/F	Vague upper abdominal pain after fatty meals	Situs inversus totalis	35 mins	None	Chronic Cholecystitis
2	29/F	Incidental findings of cholelithiasis (3-6 mm) during pregnancy	* Partial situs inversus	43 mins	None	Chronic Cholecystitis
3	38/F	Upper abdominal fullness following food.	Situs inversus totalis	48 mins	None	Chronic Cholecystitis
4	33/F	Vague upper abdominal pain.	Situs inversus totalis	44 minutes	None	Chronic Cholecystitis

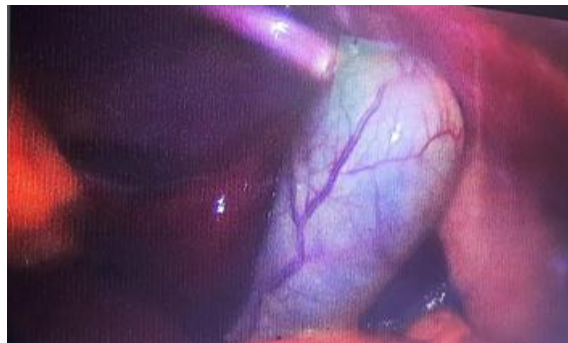

Figure 1: Location of gall bladder to the left of ligamentum teres in situs inversus totalis patient

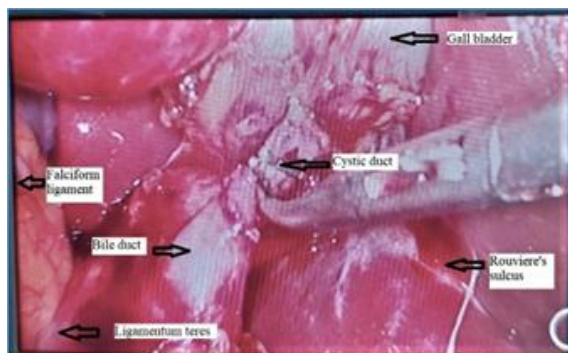


Figure 2: Dissection of Calot's triangle in partial situs inversus patient.

DISCUSSION

Total situs inversus is a rare occurrence with documented incidence being 1 in 5000-20,000 population.^[3] Other situations with left sided gall bladder include partial situs inversus, and situs ambiguous or heterotaxy syndrome. In heterotaxy syndrome there is a mixed distribution of upper abdominal and thoracic organs in left or right side of the body, isomerism of left or right atria, and

polysplenia or asplenia. Heterotaxy syndrome is believed to occur as a result of abnormal left-right axis formation in early phases of fetal development.^[4,5]

Malposition of the gall bladder such as sinistroposition or medioposition are much rare conditions associated with left sided gall bladder. Sinistroposition is believed to result from origin of the gall bladder bud from the hepatic diverticulum and thus cystic duct crosses the CBD anteriorly and joins the CBD at its right side. Alternatively this left sided location of the gall bladder may have resulted from origin of the gall bladder from the left hepatic diverticulum. So, the gall bladders are found to the left of the ligamentum teres and below the segment III of liver, and cystic duct joins the CBD into its left side. The other situation is a medioposition where the gall bladder is found to the right of the ligamentum teres and is attached to the undersurface of the quadrate lobe.^[6]

Although the chances of gall bladder pathology do not increase with the incidence of situs inversus or malposition of gall bladder, the diagnosis of gall bladder diseases remain difficult in view of atypical site of symptoms.

Campos and Sipes described the first case of laparoscopic cholecystectomy in a patient with situs inversus in 1991.^[7] Surgeons, particularly a right handed surgeon may not be very comfortable in carrying out any procedure in situs inversus patients with the same ease as doing for a situs solitus patient.^[5,6] As gall bladder disorders are very common pathology, surgeons may come across with a patient with left sided gall bladder requiring laparoscopic cholecystectomy. A thorough pre-planning with incorporation of modifications of instrument use makes the procedure safe without adding significant procedural time. The variation of

techniques for laparoscopic cholecystectomy in a left sided gall bladder include appropriate positioning of the patient, altering ports for instrument uses, and adopting alternative dissection techniques.

Course of cystic duct and cystic arteries may be aberrant in patients with left sided gall bladder. The cystic artery may cross in front of the bile duct from right to left, particularly in malposition of gall bladders. Cystic duct may also cross the CBD anteriorly and join at the right lateral aspect of CBD. So, the identification of the cystic duct bile duct junction is essential to avoid bile duct injury in cholecystectomy for left sided gall bladder.

A retrospective review identified the incidence of bile duct injury during laparoscopic cholecystectomy for a left sided gall bladder to be approximately 7.3% compared to that of cholecystectomy done for orthotopic gall bladder which is approximately 0.4 – 1.5%.^[8,9] Intraoperative cholangiogram may be of help in difficult Calot's dissection.^[10] Another option to visualize the gall bladder and the ductal structures is the use of fluorescence cholangiography. Injecting indocyanine green 30 minutes before incision time helps identification of the ductal structures at the liver hilum accurately. This modification is of particular help in situations with presumed 'difficult Calot's triangle' resulting from acute inflammation. However, the required infrastructure is not easily available with general surgeons.^[11]

CONCLUSION

Laparoscopic cholecystectomy may be carried out in situs inversus patients safely with appropriate preoperative preparation, recognition of the structures of Calot's triangle on the mirror images and adoption of some technical modifications with acceptable outcome.

REFERENCES

1. Enciu O, Toma EA, Tulin A, Georgescu DE, Miron A. Look beyond the Mirror: Laparoscopic Cholecystectomy in Situs Inversus Totalis-A Systematic Review and Meta-Analysis

- (and Report of New Technique). *Diagnostics* (Basel). 2022 May 19;12 (5):1265. doi: 10.3390/diagnostics12051265. PMID: 35626419; PMCID: PMC9140146.
2. Chaouch MA, Jerraya H, Dougaz MW, Nouira R, Dziri C. A Systematic Review of Laparoscopic Cholecystectomy in Situs Inversus. *J Invest Surg*. 2021 Mar;34(3):324-333. doi: 10.1080/08941939.2019.1622822. Epub 2019 Jun 4. PMID: 31164015
3. Pahwa HS, Kumar A, Srivastava R. Laparoscopic cholecystectomy in situs inversus: points of technique. *BMJ Case Rep*. 2012 Jun 5;2012:bcr2012006170. doi: 10.1136/bcr-2012-006170. PMID: 22675150; PMCID: PMC4543061.
4. Salama IA, Abdullah MH, Houseni M. Laparoscopic cholecystectomy in situs inversus totalis: Feasibility and review of literature. *Int J Surg Case Rep*. 2013;4(8):711-5. doi: 10.1016/j.ijscr.2013.02.030. Epub 2013 May 6. PMID: 23810920; PMCID: PMC3710908.
5. Teele SA, Jacobs JP, Border WL, Chanani NK. Heterotaxy Syndrome: Proceedings From the 10th International PCICS Meeting. *World J Pediatr Congenit Heart Surg*. 2015 Oct;6(4):616-29. doi: 10.1177/2150135115604470. PMID: 26467876.
6. Malla S, Karki S, Bohara S, Upadhaya Regmi B, Bhat PS, Sedhai S, Paudel S, Rawal SB. Sinistroposition: A case report on incidental finding of left sided gall bladder on laparoscopic cholecystectomy. *Ann Med Surg* (Lond). 2022 Sep 3;81:104547. doi: 10.1016/j.amsu.2022.104547. PMID: 36147104; PMCID: PMC9486847.
7. Campos L, Sipes E. Laparoscopic cholecystectomy in a 39-year-old female with situs inversus. *J Laparoendosc Surg*. 1991;1(2):123-5; discussion 126. doi: 10.1089/lps.1991.1.123. PMID: 1834260.
8. Abongwa, Hariscine K. MD*; De Simone, Belinda MD*; Alberici, Laura MD* et al. Implications of Left-sided Gallbladder in the Emergency Setting: Retrospective Review and Top Tips for Safe Laparoscopic Cholecystectomy. *Surgical Laparoscopy, Endoscopy & Percutaneous Techniques* 27(4):p 220-227, August 2017. | DOI: 10.1097/SLE.0000000000000417
9. de'Angelis N, Catena F, Memeo R, Coccolini F, Martínez-Pérez A et al. 2020 WSES guidelines for the detection and management of bile duct injury during cholecystectomy. *World J Emerg Surg*. 2021 Jun 10;16(1):30. doi: 10.1186/s13017-021-00369-w. PMID: 34112197; PMCID: PMC8190978.
10. Patle NM, Tantia O, Sasmal PK, Khanna S, Sen B. Laparoscopic cholecystectomy in situs inversus-our experience of 6 cases. *Indian J Surg*. 2010 Oct;72(5):391-4. doi: 10.1007/s12262-010-0159-4. Epub 2010 Nov 18. PMID: 21966139; PMCID: PMC3077135.
11. Rungsakulkij N, Tangtawee P. Fluorescence cholangiography during laparoscopic cholecystectomy in a patient with situs inversus totalis: a case report and literature review. *BMC Surg*. 2017 Apr 20;17(1):43. doi: 10.1186/s12893-017-0242-x. PMID: 28427402; PMCID: PMC5397776.